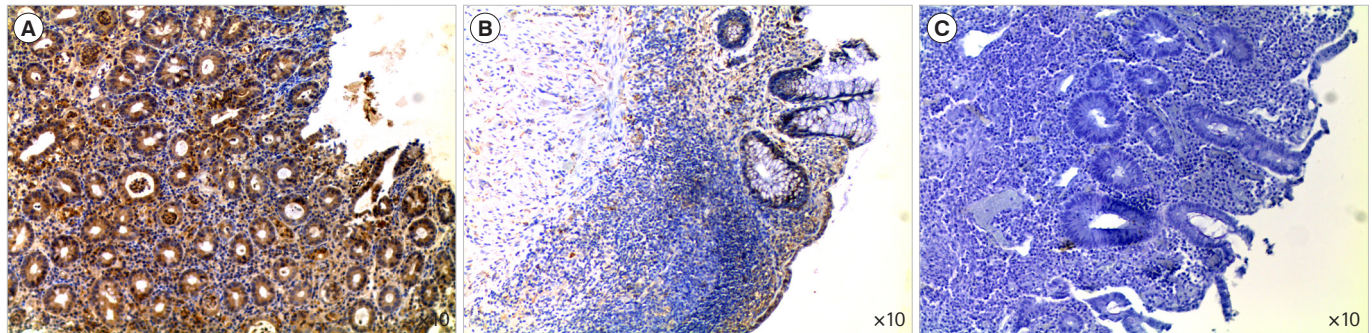


See “Colonic oncostatin M expression evaluated by immunohistochemistry and infliximab therapy outcome in corticosteroid-refractory acute severe ulcerative colitis” on pages 381-385 .



**Supplementary Fig. 1.** Representative figure demonstrating oncostatin M (OSM) immunostaining in colonic biopsy specimens. High (A) and low (B) epithelial and stromal OSM immunostaining in a colonic biopsy specimen from a patient with acute severe ulcerative colitis (ASUC). (C) Absence of OSM immunostaining in the negative control.