



# Treatment of primary sclerosing cholangitis combined with inflammatory bowel disease

You Sun Kim<sup>1,2</sup>, Edward H. Hurley<sup>3,4</sup>, Yoojeong Park<sup>1,4</sup>, Sungjin Ko<sup>1,4</sup>

<sup>1</sup>Department of Pathology, University of Pittsburgh School of Medicine, Pittsburgh, PA, USA; <sup>2</sup>Department of Internal Medicine, Kangdong Sacred Heart Hospital, Hallym University College of Medicine, Seoul, Korea; <sup>3</sup>Department of Pediatrics and <sup>4</sup>Pittsburgh Liver Research Center, University of Pittsburgh School of Medicine, Pittsburgh, PA, USA

Primary sclerosing cholangitis (PSC) is a progressive cholestatic, inflammatory, and fibrotic disease that is strongly associated with inflammatory bowel disease (IBD). PSC-IBD represents a unique disease entity and patients with this disease have an increased risk of malignancy development, such as colorectal cancer and cholangiocarcinoma. The pathogenesis of PSC-IBD involves genetic and environmental factors such as gut dysbiosis and bile acids alteration. However, despite the advancement of disease characteristics, no effective medical therapy has proven to have a significant impact on the prognosis of PSC. The treatment options for patients with PSC-IBD do not differ from those for patients with PSC alone. Potential candidate drugs have been developed based on the pathogenesis of PSC-IBD, such as those that target modulation of bile acids, inflammation, fibrosis, and gut dysbiosis. In this review, we summarize the current medical treatments for PSC-IBD and the status of new emerging therapeutic agents. (**Intest Res 2023;21:420-432**)

**Key Words:** Inflammatory bowel disease; Primary sclerosing cholangitis; Therapeutics

## INTRODUCTION

Inflammatory bowel disease (IBD) is a chronic and relapsing inflammatory disorder of the gastrointestinal tract that comprises ulcerative colitis (UC) and Crohn's disease (CD). IBD is a global disease with a recent increasing incidence and prevalence in Asian countries,<sup>1-4</sup> and Asian countries are classified into the acceleration in incidence of the epidemiological stages.<sup>5</sup> IBD patients require life-long treatment and may experience diverse extraintestinal manifestations throughout their lifetime.<sup>6-8</sup>

Primary sclerosing cholangitis (PSC) is the most trouble-

some hepatobiliary manifestation of IBD. PSC is a chronic progressive cholestatic, inflammatory and fibrotic disease, which is characterized by intrahepatic and extrahepatic biliary strictures.<sup>9,10</sup> The association between IBD and PSC is remarkable; in particular, UC is strongly associated with PSC, and up to 80% of patients with PSC also have UC.<sup>10,11</sup> The prevalence of PSC in IBD patients is approximately 8% in North America and Europe,<sup>12</sup> whereas, the prevalence rates of PSC among Asian IBD patients are lower than those in Western countries and range from 0.39% to 2.3%.<sup>13-16</sup> This discrepancy may reflect the variations in disease genotypes and phenotypes between Asian and Western countries.<sup>17,18</sup> PSC-IBD patients appear to have a distinct phenotype from classical IBD, and features such as male predominance, rectal sparing, extensive colitis, and backwash ileitis are commonly observed.<sup>9,10,15</sup> The intestinal inflammation in PSC-IBD patients tends to have mild disease activity in endoscopy and also presents mild cryptitis on histologic examination.<sup>19</sup> Indeed, PSC-IBD patients have less aggressive clinical course of IBD than classical IBD patients, as indicated

Received April 4, 2023. Revised April 28, 2023. Accepted April 29, 2023.  
**Correspondence** to Sungjin Ko, Department of Pathology, University of Pittsburgh School of Medicine, 200 Lothrop Street S-424 BST, Pittsburgh, PA 15261, USA. Tel: +1-412-383-8922, E-mail: sungjin@pitt.edu  
**Co-Correspondence** to You Sun Kim, Department of Internal Medicine, Kangdong Sacred Heart Hospital, Hallym University College of Medicine, 150 Seongan-ro, Gangdong-gu, Seoul 05355, Korea. Tel: +82-2-2224-2562, E-mail: yousunk69@korea.com

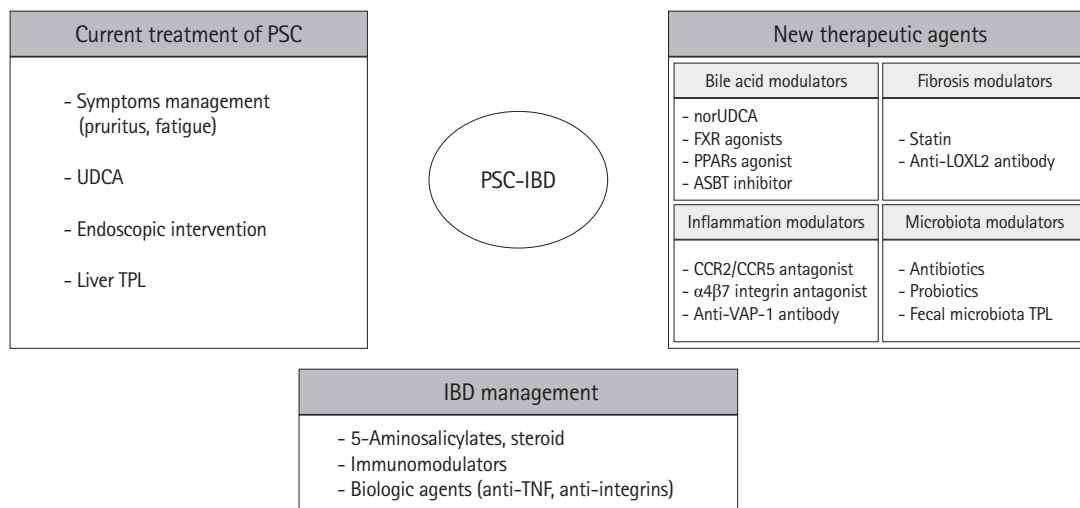
by reduced use of steroids, decreased hospitalizations and a less frequent need for immunosuppression.<sup>10,19,20</sup> However, the risk of malignancy, such as colorectal cancer and cholangiocarcinoma, is remarkably increased in PSC-IBD patients. Patients with PSC-IBD had a 4-fold higher risk of colorectal cancer, which is diagnosed at an earlier age and 28 times greater risk of cholangiocarcinoma compared to patients with IBD alone.<sup>21</sup> Therefore, PSC-IBD patients need strict surveillance and monitoring strategies for early detection of malignancy.<sup>21-25</sup>

PSC and IBD can be diagnosed at various points in time. IBD may manifest prior to or at the same time as PSC. Additionally, PSC can be diagnosed after proctocolectomy and IBD may be apparent at a late stage of PSC.<sup>26</sup> In IBD patients, the early diagnosis of PSC is challenging. Concurrent PSC is usually asymptomatic or shows mild symptoms, such as fatigue. Usually, PSC can be diagnosed in longstanding IBD patients when biochemical screening reveals abnormal findings of liver chemistry, such as serum alkaline phosphatase (ALP). Therefore, if PSC is not suspected, it may be underdiagnosed in patients with IBD. Recent guidelines recommend that PSC should be considered in IBD patients when they show symptoms of cholestasis.<sup>25</sup> Moreover, IBD activity can be mild in patients with PSC, therefore, in newly diagnosed patients with PSC, ileocolonoscopy with biopsies should be performed to detect coexistent IBD early.<sup>25</sup>

The exact pathogenesis of PSC-IBD remains poorly understood and appears to be complex. However, recent studies suggest that multiple factors are involved in the pathogenesis of PSC-IBD including genetic susceptibility, the innate and adaptive immune-mediated pathway, altered bile acids homeostasis, and gut dysbiosis.<sup>27-29</sup> The gut–liver axis plays an important role in the pathogenesis of PSC-IBD, just as gut inflammation influences the liver through immune cells, microbiota and modification of bile acids, which are derived from the liver and also affect the gut.<sup>30</sup> Although much progress has been made in understanding the pathogenesis of PSC-IBD, effective therapeutic options are still lacking. In this review, we summarize the current treatment modalities and introduce emerging potential pharmaceutical agents for patients with PSC-IBD (Fig. 1).

**CURRENT TREATMENT MODALITIES OF PSC-IBD**

Currently, there are no proven medications for the treatment of PSC. Despite PSC being an immune-mediated disease, several immunosuppressants, including corticosteroids, methotrexate, and tacrolimus, failed to demonstrate effectiveness in the treatment of PSC.<sup>31,32</sup> Medical therapy is usually intended to manage symptoms such as pruritus and fatigue and complications of PSC. Liver transplantation (TPL) is required for



**Fig. 1.** Therapeutic approach of primary sclerosing cholangitis (PSC) combined with inflammatory bowel disease (IBD). IBD management should be continued regardless of PSC treatment. Symptomatic care and management of complications of PSC are currently implemented, however, with the advancement of understanding of pathogenesis of PSC-IBD, several new therapeutic agents are developed and undergone the clinical trials. UDCA, ursodeoxycholic acid; TPL, transplantation; norUDCA, norursodeoxycholic acid; FXR, farnesoid X receptor; PPARs, peroxisome proliferator-activated receptors; ASBT, apical sodium-dependent bile acid transporter; LOXL2, lysyl oxidase-like 2; CCR2, C-C chemokine receptor 2; CCR5, C-C chemokine receptor 5;  $\alpha 4\beta 7$ , alpha 4 beta 7; VAP-1, vascular adhesion protein 1; TNF, tumor necrosis factor.

patients with advanced PSC. At present, the treatment options for patients with PSC-IBD do not differ from the patients with PSC alone. Besides PSC treatment, patients with PSC-IBD should continue the management of intestinal inflammation. The survival of patients with PSC-IBD was significantly worse than that of patients with IBD-only ( $P=0.001$ ).<sup>33</sup> Moreover, the co-existence of IBD was the risk factor of PSC recurrence after liver TPL.<sup>34</sup>

### 1. IBD Treatment

According to IBD treatment guidelines, the use of 5-aminosalicylic acid, steroids, thiopurines, and biologics such as anti-tumor necrosis factor (TNF) agents is recommended to control the activity of bowel inflammation in patients with PSC-IBD.<sup>35</sup> However, steroids and thiopurines do not improve the clinical course of combined PSC.<sup>36</sup> Anti-TNF agents are commonly used in patients with moderate to severe IBD. Whether patients with PSC-IBD respond to anti-TNF agents similarly to patients with IBD-only is uncertain. In addition, there is a concern regarding the risk of infectious complications, such as cholangitis, when treating patients with anti-TNF agents. In a small randomized controlled trial (RCT) that evaluated the use of infliximab for 6 months in patients with PSC ( $n=10$ ), infliximab did not demonstrate efficacy without risk of infection.<sup>37</sup> The retrospective analysis of 141 patients with PSC-IBD with anti-TNF agents (infliximab or adalimumab) for 3 months revealed that 48% of patients responded to anti-TNF agents in IBD disease activity, suggesting an attenuated response compared with patients with IBD-only patients, in which the early response rate was reported as more than 60%.<sup>38,39</sup> Moreover, limited effects were observed on serum ALP level. At 3 months, the adalimumab group ( $n=23$ ) showed a median 15% reduction in serum ALP level compared to base line ( $P=0.001$ ), whereas infliximab group ( $n=66$ ) showed a median 4% reduction in serum ALP level ( $P=0.306$ ). At 12 months, the adalimumab group ( $n=14$ ) had a 33% reduction in serum ALP level, although it was not significant ( $P=0.11$ ). In terms of safety, anti-TNF agents did not exacerbate PSC symptoms or side effects such as cholangitis.<sup>40</sup>

Another retrospective study also found that adalimumab ( $n=19$ ) treatment showed a significant decrease in serum ALP after 6 to 8 months ( $P=0.03$ ), but the decrease was not significant after 12 to 14 months ( $P=0.24$ ). Infliximab treatment showed no improvement in serum ALP level.<sup>41</sup> Therefore, treatment with anti-TNF agents is effective in patients with PSC-IBD in terms of IBD activity control, but the response rates are decre-

ased compared to those in patients with IBD-only. Evidence on the effects of anti-TNF agents on combined PSC is limited, and only adalimumab shows initial response; however, sample size is too small to draw conclusions. Moreover, considering the retrospective study design, future prospective studies on the effect of adalimumab on PSC-IBD are needed to elucidate its mechanism of action. In terms of safety, the use of thiopurines or anti-TNF agents has no harmful effects on the risk of infection or clinical outcomes of PSC-IBD.<sup>37,40-42</sup>

Vedolizumab is a selective IgG1 monoclonal antibody that binds to  $\alpha4\beta7$  integrin, which is expressed on intestinal lymphocytes. Vedolizumab inhibits the  $\alpha4\beta7$  integrin-mucosal addressin cellular adhesion molecule-1 (MAdCAM-1) interaction, which blocks lymphocyte trafficking to inflammation site of the gastrointestinal tract.<sup>43</sup> Vedolizumab is currently used as an effective treatment modality for IBD.<sup>44,45</sup> Considering the mechanism of action of the drug and the over-expression of MAdCAM-1 in the hepatic endothelial cells of PSC, vedolizumab was expected to be a potential candidate for the treatment of PSC-IBD. In a large retrospective study by the International PSC Study Group, 102 patients with PSC-IBD who received at least 3 doses of vedolizumab were evaluated.<sup>46</sup> Of these patients, 56.8% showed endoscopic improvement of IBD, whereas, only 20.6% of them showed serum ALP reduction by 20% or more. Additionally, 20.6% of patients were accompanied by liver-related adverse events.<sup>46</sup>

Another retrospective study of patients with PSC-IBD who were treated with vedolizumab ( $n=75$ ) showed that only 4 patients (11%) had benefited from as reduction of serum ALP at 54 weeks posttreatment, indicating a lack of effectiveness of vedolizumab on liver function in patients with PSC-IBD.<sup>47</sup> Therefore, despite the significant effectiveness of vedolizumab on the treatment of IBD, the improvement of concomitant PSC was limited. As such, a phase III trial using vedolizumab in patients with PSC-IBD was withdrawn (NCT03035058).<sup>48</sup>

### 2. Ursodeoxycholic Acid

The most widely used drug in the treatment of PSC is ursodeoxycholic acid (UDCA). The mechanism of action of UDCA includes stimulation of hepatocellular and cholangiocellular secretion, anti-apoptosis and reduction of bile acids toxicity.<sup>49</sup> However, the exact mechanism of UDCA still has uncertainty.<sup>50</sup>

Biochemical improvements were demonstrated after treatment of low dose UDCA (13–15 mg/kg/day) in patients with PSC, however, there were no differences in time to treatment failure or time to liver TPL between UDCA and placebo.<sup>51,52</sup> In

addition, treatment of moderate dose UDCA (17–23 mg/kg/day) for a longer period (5 years) failed to reduce mortality or liver TPL rate.<sup>53</sup> Another RCT with high dose UDCA (28–30 mg/kg/day) also failed to demonstrate any benefits but showed higher rates of serious adverse events.<sup>54</sup> Therefore, recent UK-PSC treatment guideline recommends against the routine use of UDCA for newly diagnosed PSC patients.<sup>55</sup> However, use of UDCA at low or moderate dose is still prevalent in clinical practice in many countries. In addition, UDCA withdrawal for 3 months caused a significant worsening of liver chemistry.<sup>56</sup> The American Association for the Study of Liver Diseases practice guidance suggests that patients with a persistently elevated serum ALP can be considered for UDCA treatment at 13–23 mg/kg/day.<sup>25</sup> Nevertheless, considering limited evidence of UDCA in long-term outcomes of PSC, effective medical therapy is still unmet need and novel therapy is necessary.

### 3. Endoscopic Intervention

PSC can lead to significant bile duct stenosis at all levels in the biliary tree. Dominant strictures are present in up to 45% of PSC patients and if accompanied with impaired bile flows and worsening cholestasis, endoscopic intervention is required with balloon dilatation or stent insertion to relieve the dominant strictures.<sup>57</sup> Balloon dilatation is generally preferred to stent insertion given similar efficacy and lower complications such as pancreatitis, cholangitis, and bacteremia.<sup>58</sup> In cases of combined cholangitis, treatment with antibiotics should be initiated.<sup>59</sup>

### 4. Liver TPL

Advanced liver disease attributed to PSC is a well-established indication for liver TPL. Indeed, liver TPL is the most reliable and effective treatment of PSC and is the fifth most common indication for total adult liver TPL in the United States.<sup>60</sup> Treatment guideline recommended patients with PSC should be referred for consideration of liver TPL if there are any liver-related complications.<sup>55</sup> The outcomes of PSC-related liver TPL are excellent with 5-year survival rates of 80% to 85%.<sup>61</sup> However, even after liver TPL, there is a risk for PSC recurrence. PSC recurrence was reported about 20% and the coexistence of IBD was the risk factor of PSC recurrence (hazard ratio [HR], 1.73).<sup>34</sup> Further, active IBD at the time of liver TPL is presumed as a significant risk factor of graft failure (HR, 10;  $P=0.001$ ).<sup>10,62</sup> Therefore, patients with PSC-IBD should be maintained in remission state of IBD activity by the time of liver TPL to improve the outcome.<sup>62</sup>

## NEW THERAPEUTIC AGENTS

Understanding the pathogenesis of PSC-IBD is essential for identifying new therapeutic modalities, and providing opportunities for developing new therapeutic agents.<sup>48,49,63</sup> Several potential candidate drugs are undergoing clinical trials (Table 1). Most clinical trials of new therapeutic agents include more than 50% of concomitant IBD patients.

### 1. Bile Acids Modulators

PSC is one of cholestatic liver disease which is characterized by accumulation of toxic bile acids in liver. Altered bile acids composition is also regarded as an important pathogenetic contributor. Considering the toxic effects of bile acids on cholangiocytes, several potential drugs targeting bile acids modulation are developed to improve the cholestasis, increase the bicarbonate secretion and bile acids regulation.<sup>48,49,64</sup>

#### 1) Norursodeoxycholic Acid

New derivative of UDCA, 24-norursodeoxycholic acid (norUDCA) is a side chain shortened C23 homologue of UDCA. norUDCA is able to undergo cholehepatic shunting and stimulate bicarbonate secretion by cholangiocytes.<sup>65</sup> In animal models, norUDCA has shown remarkable anti-cholestatic, anti-inflammatory, anti-fibrotic, and anti-proliferative effects,<sup>65,66</sup> suggesting it may be effective in cholestatic liver disease including PSC. A phase II RCT was conducted to evaluate the safety and efficacy of norUDCA (500, 1,000, or 1,500 mg/day) in patients with PSC. Treatment for 12 weeks showed significant reductions of serum ALP in a dose-dependent manner with an excellent safety profile.<sup>64</sup> These therapeutic effects are not associated with concomitant IBD presence. In addition, norUDCA had no effect on IBD activity. A larger phase III study of long-term efficacy of norUDCA 1,500 mg/day is ongoing.

#### 2) Farnesoid X Receptor Agonists

Other bile acids related agents are farnesoid X receptor (FXR) agonists such as endogenous FXR ligands or nonsteroidal FXR agonists. FXR, a nuclear receptor for signaling of bile acids, plays an important role in bile acids homeostasis. Obeticholic acid (OCA), a native FXR ligand has been shown to regulate bile acids transport as well as possessing anti-inflammatory and anti-fibrotic effects.<sup>67</sup> A phase II RCT with high dose of OCA (5–10 mg/day) in patients with PSC revealed a significant decrease of serum ALP compared to placebo after 24 weeks treatment ( $P=0.043$ ), although a higher rate of pruritus was observed

Table 1. Novel Therapies for the Treatment of PSC-IBD Patients

Class	Drug	Mechanism	Study design	No.	Combined with IBD, No. (%)	Route	Treatment duration	Main results	Reference
Bile acids modulators	norUDCA	Side chain-shortened C23 homologue of UDCA	RCT, phase II	159	101 (63.5)	Oral	12 wk	Reduction of serum ALP by -12.3%, -17.3%, and -26.0% in the 500, 1,000, and 1,500 mg/day groups (P=0.029, P=0.003, and P<0.0001)	Fickert et al. (2017) <sup>64</sup>
	Obeticholic acid	Endogenous FXR ligand	RCT, phase II	76	43 (56.6)	Oral	24 wk	Reduction of serum ALP in OCA 5-10 mg group (least-square mean difference = -83.4 U/L, P=0.043)	Kowdley et al. (2020) <sup>68</sup>
	Cilofexor	Synthetic FXR agonist	RCT, phase II	52	31 (60)	Oral	12 wk	Reduction of serum ALP by -21% (P=0.029), rGT (-30%; P<0.001), ALT (-49%; P=0.009)	Trauner et al. (2019) <sup>69</sup>
	All-trans-retinoic acid	FXR activators	Human pilot study	15	12 (80)	Oral	12 wk	No significant decrease of serum ALP (P=0.09), reduction of serum ALT (76±55 to 46±32 U/L, P=0.001) and bile acids intermediates C4 (9.8±19 to 7.9±11 ng/mL, P=0.03)	Assis et al. (2017) <sup>70</sup>
Bezafibrate	Bezafibrate	PPARs agonist	Retrospective study	20	14 (70)	Oral	Median 1.56 yr	Reduction of serum ALP by 41% at 3 mo (P=0.0002). Pruritus was significantly decreased	Lemoine et al. (2018) <sup>71</sup>
	Bezafibrate	PPARs agonist	RCT, phase III	104 planned	NC	Oral	24 mo	Ongoing	<a href="https://clinicaltrials.gov/study/Nct04309773">https://clinicaltrials.gov/study/Nct04309773</a> <sup>72</sup>
Inflammation modulators	Genirciviroc	CCR2 & CCR5 antagonist	Single-arm, open-label, exploratory study, phase II	24	17 (71)	Oral	24 wk	Reduction of serum ALP; median absolute reduction of 49.5 U/L (18.0%, range: -46%, 89%)	Eksteen et al. (2021) <sup>73</sup>
	Vedolizumab	α4β7 integrin antagonist	Retrospective study	102	102 (100)	IV	At least 3 infusions	Serum ALP decreased by 20% or more in 21 patients (20.6%)	Lynch et al. (2020) <sup>46</sup>
	Vedolizumab	α4β7 integrin antagonist	RCT, phase III	NC	NC	IV	NC	Withdrawn	<a href="https://clinicaltrials.gov/study/Nct03035058">https://clinicaltrials.gov/study/Nct03035058</a> <sup>74</sup>
	Timolimumab	Anti-VAP-1 antibody	Single-arm trial, phase II	59 planned	NC	IV	7 Infusions every 2 wk	Ongoing	<a href="https://clinicaltrials.gov/study/NCT02392117">https://clinicaltrials.gov/study/NCT02392117</a> <sup>75</sup>
Fibrosis modulators	Statin	HMG-CoA reductase	A population-based cohort, retrospective study	404	404 (100)	Oral	Exposure to statins between 2005 and 2016	A reduced risk of all-cause mortality (HR, 0.68; 95% CI, 0.54-0.88) and death or liver TPL (HR, 0.50; 95% CI, 0.28-0.66)	Stokkelan et al. (2019) <sup>76</sup>
	Statin (simvastatin) 40 mg/day	HMG-CoA reductase	RCT, phase III	700 planned	NC	Oral	60 mo	Ongoing	Bergquist et al. (2022) <sup>77</sup>
Simtuzumab	Anti-lysyl oxidase-like 2 antibody	RCT, phase II	235	112 (48)	SQ	96 wk	Fibrosis progression in 80 patients (34%), PSC-related clinical events in 47 patients (20%)	Muir et al. (2019) <sup>78</sup>	

(Continued to the next page)

Table 1. Continued

Class	Drug	Mechanism	Study design	No.	Combined with IBD, No. (%)	Route	Treatment duration	Main results	Reference
Microbiota modulators	Metronidazole	Antibiotics	RCT	80	65 (81)	Oral	36 mo	Reduction of serum ALP ( $P < 0.05$ ) and Mayo risk score ( $P < 0.01$ ). Histologic improvement of stage ( $P = 0.047$ ) or grade ( $P = 0.014$ ) in metronidazole group	Färkkilä et al. (2004) <sup>79</sup>
	Vancomycin	Antibiotics	RCT	35	25 (71)	Oral	12 wk	Reduction of serum ALP ( $P < 0.05$ ) and clinical score ( $P < 0.05$ )	Tabibian et al. (2013) <sup>80</sup>
	Vancomycin	Antibiotics	RCT II/III	102	NC	Oral	18 mo	Ongoing	https://clinicaltrials.gov/study/Nct03710122 <sup>81</sup>
	4 Lactobacillus, 2 Bifidobacillus	Probiotics	RCT, crossover	14	14 (100)	Oral	12 wk	No change in clinical symptoms and liver biochemistry	Vleggaar et al. (2008) <sup>82</sup>
	Fecal microbiota transplantation	Microbiome	Open pilot study, phase I/II	10	10 (100)	Colonoscopy	Single FMT and assessed after 24 wk	Three patients showed serum ALP reduction of at least 50%	Allegrretti et al. (2019) <sup>83</sup>

PSC, primary sclerosing cholangitis; IBD, inflammatory bowel disease; norUDCA, norursodeoxycholic acid; UDCA, ursodeoxycholic acid; RCT, randomized controlled trial; ALP, alkaline phosphatase; FXR, farnesoid X receptor; OCA, obeticholic acid; rGT, gamma glutamyl transpeptidase; ALT, alanine transaminase; PPARs, peroxisome proliferator-activated receptors; NC, not commented; CCR2, C-C chemokine receptor 2; CCR5, C-C chemokine receptor 5;  $\alpha 4\beta 7$ , alpha 4 beta 7; IV, intravenous; VAP-1, vascular adhesion protein 1; HMG-CoA, 3-hydroxy-3-methylglutaryl coenzyme A; HR, hazard ratio; CI, confidence interval; SQ, subcutaneous; IPL, transplantation.

in the OCA group.<sup>68</sup> Regarding concomitant UC, no clear treatment or dose-related differences were observed. A majority of patients with UC had remission state at enrollment and maintained the remission state to week 24.

Cilofexor is a synthetic FXR agonist which has shown anti-inflammatory and anti-fibrotic effects. In a phase II RCT, cilofexor 100 mg/day for 12 weeks treatment in patients with PSC decreased serum ALP with tolerable safety ( $P = 0.029$ ).<sup>69</sup> All patients with IBD had quiescent disease at enrollment and no patient had exacerbation of IBD activity during treatment. A phase III RCT with cilofexor is currently ongoing.

All-trans-retinoic acid is an indirect activator of the FXR transcription complex. A pilot study was conducted with combination therapy of all-trans-retinoic acid (45 mg/m<sup>2</sup>/day) and UDCA for 12 weeks. Although there was no significant decrease of serum ALP ( $P = 0.09$ ), significant reduction of alanine transaminase and the bile acids intermediates were observed.<sup>70</sup>

**3) Peroxisome Proliferator-Activated Receptors Agonists**

Peroxisome proliferator-activated receptors (PPARs) play a critical role in the regulation of bile acids homeostasis via increase of biliary phospholipid secretion, bile acids detoxification, and inhibition of bile acids synthesis.<sup>84-86</sup> PPARs also have anti-inflammatory effects through reduction in nuclear factor- $\kappa$ B dependent gene activation and inflammatory cytokines as well as anti-fibrotic effects.<sup>87</sup> Bezafibrate is an agonist of PPAR $\alpha/\gamma$  and the efficacy of bezafibrate in combination with UDCA has been demonstrated in patients with primary biliary cholangitis, another cholestatic liver disease.<sup>88</sup> In a retrospective study, 20 PSC patients were treated with bezafibrate (400 mg/day) or fenofibrate (200 mg/day) combined with UDCA and showed a reduction of serum ALP by 41% at 3 months ( $P = 0.0002$ ).<sup>71</sup> Of the 14 concomitant IBD patients, 1 patient experienced IBD flare and discontinued the fibrate. A phase III RCT with bezafibrate is currently ongoing for the PSC patients with persistent cholestasis despite standard UDCA therapy.

**4) Apical Sodium-Dependent Transporter Inhibitors**

Several inhibitors of apical sodium-dependent bile acid transporter (ASBT) are also ongoing in clinical trials.<sup>48</sup> Inhibition of ASBT blocks ileal bile acids reuptake, and reduces the amount of enterohepatic circulation of bile acids. Currently, ASBT inhibitors are considered promising candidate drugs for cholestatic disease including PSC.

## 2. Inflammation Modulators

Through genetic studies, PSC is recognized as the immune-mediated disease. In fact, both innate and adaptive immune pathway are involved in the pathogenesis of PSC-IBD.<sup>89-91</sup>

### 1) C-C Chemokine Receptor 2/5 Antagonists

Monocyte chemoattractant protein-1 is overexpressed in PSC patients in accordance with dysregulated innate immunity.<sup>92</sup> When hepatobiliary tract receives the injuries, C-C chemokine receptor (CCR) 2 and CCR5, the main receptors of monocyte chemoattractant protein-1, are rapidly activated and induce macrophage and monocytes infiltration, hepatic stellate cells (HSC) activation, leading to hepatic inflammation and fibrogenesis.<sup>92,93</sup> In addition, CCR5 is highly expressed in active IBD and the lymphocyte grade has a positive correlation with CCR5 expression, suggesting the possibility of new therapies of CCR5 antagonist for IBD.<sup>94</sup> Cenicriviroc, a novel antagonist of CCR2 and CCR5, underwent a phase II open-label trial, and only showed a limited reduction (median 18%) of serum ALP after 24 weeks treatment.<sup>73</sup> Concomitant IBD patients were remission state (n = 15) or had mild disease activity (n = 4). During 24 weeks, no IBD flare was reported. Despite cenicriviroc not achieving the primary endpoint, it is still suggested to be a possible candidate drug for PSC, although further study is necessary to define the optimal dose.

### 2) Anti-Vascular Adhesion Protein Antibody

Timolimumab is a monoclonal anti-vascular adhesion protein-1 antibody. Vascular adhesion protein-1 is an adhesion molecule expressed by hepatic endothelial cells, which enables activated T cells to bind to hepatic endothelium.<sup>95</sup> The action of mechanism of timolimumab is reduction of leukocyte trafficking to site of inflammation. A phase II single-arm trial of timolimumab is ongoing with the primary endpoint of the decrease of serum ALP from baseline.<sup>48</sup>

## 3. Fibrosis Modulators

PSC is a progressive inflammatory disorder causing activation of HSC and ultimately lead to the peribiliary fibrosis. Therefore, anti-fibrotic mechanisms are important potential target for PSC treatment.<sup>96</sup>

### 1) Statins

Statins administration displayed clinical benefits to liver disease patients through anti-inflammatory/fibrotic effects in addition to cholesterol lowering effects.<sup>97</sup> In a Swedish PSC-IBD

cohorts (n = 2,914), 13.9% of patients were exposure to statins and statins use reduced death or liver TPL (HR, 0.50), suggesting an association between treatment with statins and improved outcomes in PSC-IBD patients.<sup>76</sup> Based on these results, a RCT is currently underway to evaluate the long-term efficacy of simvastatin on the prognosis in patients with PSC (NCT-04133792).<sup>77</sup>

### 2) Anti-Lysyl Oxidase-like 2 Antibody

Simtuzumab, a monoclonal antibody targeting lysyl oxidase-like 2 (LOXL2) showed promising anti-fibrotic efficacy in animal model.<sup>98</sup> LOXL2 maintains the fibrogenic process through stabilization of the fibrotic matrix and promotes fibrogenic HSC. Along this line, elevation of LOXL2 in the serum and liver tissue of patients with PSC has been observed.<sup>99</sup> However, simtuzumab challenging for 96 weeks in patients with PSC failed to show significant anti-fibrotic benefits compared with placebo group in a phase IIb RCT.<sup>78</sup> Of the 112 concomitant IBD patients, 8 patients experienced IBD flare during treatment: 3 in simtuzumab group and 5 in placebo.

## 4. Microbiota Modulators

Disrupted intestinal barrier due to IBD can cause the influx of gut microbiota to hepatic circulation, leads to the hepatic inflammation of PSC. The involvement of the gut microbiota is regarded as a major contributing factor to development of PSC-IBD.<sup>27,30,100</sup> In the animal model, the epithelial barrier was disrupted by PSC-IBD patients-derived *Klebsiella pneumonia* (pathobionts) and subsequent bacterial translocation and IL-17-producing T helper 17-mediated hepatobiliary injuries were demonstrated.<sup>100</sup> Of interest, antibiotic treatment improved the T helper 17 immune response induced by *K. pneumonia*.<sup>100</sup> Furthermore, the presence of *K. pneumonia* were associated with reduced liver TPL free survival in patients with PSC-IBD.<sup>101</sup>

Gut dysbiosis is reported in patients with PSC-IBD, that is, reduced bacterial diversity and a different global microbial composition are observed.<sup>102</sup> The dysbiosis of PSC-IBD is similar to those of PSC-only patients rather than IBD-only patients.<sup>103</sup> The current evidence provides a strong rationale for clinical trials of microbiota modulators that target the dysbiosis in PSC-IBD patients.

### 1) Antibiotics

Gut dysbiosis perturbs the gut immune system and induces biliary injury via bile acids dysregulation as well as augmentation of toxin trafficking. Resolving the dysbiosis would be the

key to treating of PSC. In fact, modulating microbiota using antibiotics showed promising results in clinical trials. An RCT using metronidazole (600–800 mg/day) and co-treatment with UDCA was evaluated in 80 PSC patients.<sup>79</sup> After 30 months, serum ALP ( $P < 0.05$ ) and New Mayo PSC Risk score ( $P < 0.01$ ) decreased markedly in the metronidazole group ( $P < 0.05$ ). Nonetheless, no significant effects on disease progression were found.<sup>79</sup>

Vancomycin is a potent antibiotic against Gram-positive bacteria and is poorly absorbed, remains as high concentrations in the intestine. The RCT of oral vancomycin showed promising results in patients with PSC. Vancomycin (125–250 mg four times/day) and metronidazole were treated for 12 weeks and vancomycin group experienced significant reductions of serum ALP ( $P < 0.05$ ) and Mayo PSC risk score ( $P < 0.05$ ) with less adverse effects than metronidazole group.<sup>80</sup> Furthermore, a meta-analysis of 124 PSC patients who treated with antibiotics showed a significant reduction of serum ALP (65.6%,  $P < 0.002$ ) as well as severity of cholestasis.<sup>104</sup> Vancomycin may aid improving PSC either via direct effects on the microbiome or via host-mediated mechanisms.<sup>104</sup> A phase III RCT is undergoing to evaluate the efficacy of vancomycin in patients with PSC-IBD (NCT03710122).

## 2) Probiotics

Probiotics are live microorganisms which are expected to confer benefits to the host by regulation of intestinal microecology. Notably, each microorganism or combination of microorganisms has a distinct therapeutic potential in a diverse disease setting. There are only few studies examining the therapeutic potential of probiotics on patients with PSC-IBD (remission state of IBD activity). In a RCT of 14 PSC-IBD patients, probiotics having 4 *Lactobacillus* and 2 *Bifidobacillus* strains was tried for 3 months, however, no improvement in clinical symptoms (fatigue, pruritus, or frequency of stools) ( $P = 0.89$ ) as well as serum ALP level ( $P = 0.99$ ) were observed.<sup>82</sup> One patient in placebo group experienced IBD flare and improved by steroid treatment.

## 3) Fecal Microbiota TPL

Fecal microbial transplantation (FMT) is used to restore a healthy gut microbial environment. FMT is widely accepted as a reliable treatment option for recurrent or refractory *Clostridioides difficile* infection. Moreover, numerous trials have been performed to evaluate the efficacy and safety in various diseases including IBD and hepatic encephalopathy.<sup>105</sup> In an open pilot study of FMT in 10 PSC-IBD patients (7 patients in re-

mission, 3 patients in mild activity),<sup>83</sup> 3 patients showed serum ALP reduction of at least 50% after 24 weeks of FMT with a good safety profile. Interestingly, an increase in bacterial diversity and engraftment in post-FMT patients correlated with decreased serum ALP levels ( $P = 0.02$ ),<sup>83</sup> implying the functional involvement of dysbiosis in biliary pathology. There was no flare of IBD activity. Further studies are needed for assessing long-term efficacy of FMT in PSC-IBD patients along with the careful observation of IBD disease activity.

## CONCLUSION

Currently, there are no proven treatments that affect the clinical course of PSC-IBD. Despite PSC-IBD is classified as an immune-mediated disease, immunosuppressant treatments have proven to be ineffective. Additionally, the treatment modalities for IBD including anti-TNF agents have also limited effects on PSC prognosis, however, the safety seems acceptable. Basically, the treatment options for patients with PSC-IBD do not differ from those for patients with PSC alone. However, the increased risk of malignancy in patients with PSC-IBD needs the careful surveillance and monitoring strategies. Currently, UDCA is the most widely used drug; however, the role of UDCA in the treatment of PSC remains controversial.

Nonetheless, there are various clinical/preclinical investigation including modulation of bile acids, inflammation, fibrosis and microbiome based on the advanced understating of pathogenesis of PSC-IBD. In particular, bile acids modulators appear to be promising agents and have safety profile in terms of IBD activity. Combination therapy may be probably needed to achieve clinical efficacy.

## ADDITIONAL INFORMATION

### Funding Source

Funding was provided by NIH grant 1R01CA258449 and PLRC Pilot & Feasibility grant PF 2019-05 to Hurley EH and Ko S through 1P30DK120531-01 to the Pittsburgh Liver Research Center.

### Conflict of Interest

Kim YS is an editorial board member of the journal but was not involved in the peer reviewer selection, evaluation, or decision process of this article. No other potential conflicts of interest relevant to this article were reported.



**Data Availability Statement**

Not applicable.

**Author Contributions**

Conceptualization: Kim YS, Ko S. Supervision: Ko S. Validation: Hurley EH, Park Y, Ko S. Writing – original draft: Kim YS, Ko S. Writing – review & editing: Kim YS, Hurley EH, Park Y, Ko S. Approval of final manuscript: all authors.

**ORCID**

Kim YS <https://orcid.org/0000-0002-5156-3458>  
 Hurley EH <https://orcid.org/0000-0001-7592-7933>  
 Park Y <https://orcid.org/0009-0005-1828-7147>  
 Ko S <https://orcid.org/0000-0002-6079-5939>

**REFERENCES**

- Park SH. Update on the epidemiology of inflammatory bowel disease in Asia: where are we now? *Intest Res* 2022;20:159-164.
- Ng SC, Shi HY, Hamidi N, et al. Worldwide incidence and prevalence of inflammatory bowel disease in the 21st century: a systematic review of population-based studies. *Lancet* 2017;390:2769-2778.
- Molodecky NA, Soon IS, Rabi DM, et al. Increasing incidence and prevalence of the inflammatory bowel diseases with time, based on systematic review. *Gastroenterology* 2012;142:46-54.
- Low D, Swarup N, Okada T, Mizoguchi E. Landscape of inflammatory bowel disease in Singapore. *Intest Res* 2022;20:291-296.
- Kaplan GG, Windsor JW. The four epidemiological stages in the global evolution of inflammatory bowel disease. *Nat Rev Gastroenterol Hepatol* 2021;18:56-66.
- Mahadevan U, Silverberg MS. Inflammatory bowel disease-gastroenterology diamond jubilee review. *Gastroenterology* 2018;154:1555-1558.
- Vavricka SR, Schoepfer A, Scharl M, Lakatos PL, Navarini A, Rogler G. Extraintestinal manifestations of inflammatory bowel disease. *Inflamm Bowel Dis* 2015;21:1982-1992.
- Kim JM, Cheon JH. Pathogenesis and clinical perspectives of extraintestinal manifestations in inflammatory bowel diseases. *Intest Res* 2020;18:249-264.
- Palmela C, Peerani F, Castaneda D, Torres J, Itzkowitz SH. Inflammatory bowel disease and primary sclerosing cholangitis: a review of the phenotype and associated specific features. *Gut Liver* 2018;12:17-29.
- Rossi RE, Conte D, Massironi S. Primary sclerosing cholangitis associated with inflammatory bowel disease: an update. *Eur J Gastroenterol Hepatol* 2016;28:123-131.
- Molodecky NA, Kareemi H, Parab R, et al. Incidence of primary sclerosing cholangitis: a systematic review and meta-analysis. *Hepatology* 2011;53:1590-1599.
- Chapman R, Fevery J, Kalloo A, et al. Diagnosis and management of primary sclerosing cholangitis. *Hepatology* 2010;51:660-678.
- Singh A, Midha V, Narang V, et al. Low prevalence of primary sclerosing cholangitis in patients with inflammatory bowel disease in India. *Intest Res* 2023;21:452-459.
- Ye BD, Yang SK, Boo SJ, et al. Clinical characteristics of ulcerative colitis associated with primary sclerosing cholangitis in Korea. *Inflamm Bowel Dis* 2011;17:1901-1906.
- Weng MT, Shih IL, Tung CC, et al. Association of young age and male sex with primary sclerosing cholangitis in Taiwanese patients with inflammatory bowel disease. *Intest Res* 2022;20:224-230.
- Ohta Y, Taida T, Kato J, et al. Clinical features focusing on extraintestinal manifestations in Japanese patients with inflammatory bowel diseases: far east 1000. *Digestion* 2023;104:328-334.
- Song EM, Yang SK. Natural history of inflammatory bowel disease: a comparison between the East and the West. *Intest Res* 2022;20:418-430.
- Park SB, Yoon JY, Cha JM. What are the different phenotypes of inflammatory bowel disease in Asia? *Gut Liver* 2022;16:676-685.
- Schaeffer DE, Win LL, Hafezi-Bakhtiari S, Cino M, Hirschfield GM, El-Zimaity H. The phenotypic expression of inflammatory bowel disease in patients with primary sclerosing cholangitis differs in the distribution of colitis. *Dig Dis Sci* 2013;58:2608-2614.
- Sano H, Nakazawa T, Ando T, et al. Clinical characteristics of inflammatory bowel disease associated with primary sclerosing cholangitis. *J Hepatobiliary Pancreat Sci* 2011;18:154-161.
- Trivedi PJ, Crothers H, Mytton J, et al. Effects of primary sclerosing cholangitis on risks of cancer and death in people with inflammatory bowel disease, based on sex, race, and age. *Gastroenterology* 2020;159:915-928.
- Soetikno RM, Lin OS, Heidenreich PA, Young HS, Blackstone MO. Increased risk of colorectal neoplasia in patients with primary sclerosing cholangitis and ulcerative colitis: a meta-

- analysis. *Gastrointest Endosc* 2002;56:48-54.
23. Gulamhusein AF, Eaton JE, Tabibian JH, Atkinson EJ, Juran BD, Lazaridis KN. Duration of inflammatory bowel disease is associated with increased risk of cholangiocarcinoma in patients with primary sclerosing cholangitis and IBD. *Am J Gastroenterol* 2016;111:705-711.
  24. Oh EH, Kim YJ, Kim M, Park SH, Kim TO, Park SH. Risks of colorectal cancer and biliary cancer according to accompanied primary sclerosing cholangitis in Korean patients with ulcerative colitis: a nationwide population-based study. *Intest Res* 2023;21:252-265.
  25. Bowlus CL, Arrivé L, Bergquist A, et al. AASLD practice guidance on primary sclerosing cholangitis and cholangiocarcinoma. *Hepatology* 2023;77:659-702.
  26. Mouchli MA, Singh S, Boardman L, et al. Natural history of established and de novo inflammatory bowel disease after liver transplantation for primary sclerosing cholangitis. *Inflamm Bowel Dis* 2018;24:1074-1081.
  27. Hov JR, Karlsen TH. The microbiota and the gut-liver axis in primary sclerosing cholangitis. *Nat Rev Gastroenterol Hepatol* 2023;20:135-154.
  28. Karlsen TH, Folseraas T, Thorburn D, Vesterhus M. Primary sclerosing cholangitis: a comprehensive review. *J Hepatol* 2017;67:1298-1323.
  29. Jiang X, Karlsen TH. Genetics of primary sclerosing cholangitis and pathophysiological implications. *Nat Rev Gastroenterol Hepatol* 2017;14:279-295.
  30. Kim YS, Hurley EH, Park Y, Ko S. Primary sclerosing cholangitis (PSC) and inflammatory bowel disease (IBD): a condition exemplifying the crosstalk of the gut-liver axis. *Exp Mol Med* 2023;55:1380-1387.
  31. Boberg KM, Egeland T, Schrumpf E. Long-term effect of corticosteroid treatment in primary sclerosing cholangitis patients. *Scand J Gastroenterol* 2003;38:991-995.
  32. Talwalkar JA, Gossard AA, Keach JC, Jorgensen RA, Petz JL, Lindor RN. Tacrolimus for the treatment of primary sclerosing cholangitis. *Liver Int* 2007;27:451-453.
  33. Fraga M, Fournier N, Safroneeva E, et al. Primary sclerosing cholangitis in the Swiss Inflammatory Bowel Disease Cohort Study: prevalence, risk factors, and long-term follow-up. *Eur J Gastroenterol Hepatol* 2017;29:91-97.
  34. Steenstraten IC, Sebib Korkmaz K, Trivedi PJ, et al. Systematic review with meta-analysis: risk factors for recurrent primary sclerosing cholangitis after liver transplantation. *Aliment Pharmacol Ther* 2019;49:636-643.
  35. Rubin DT, Ananthakrishnan AN, Siegel CA, Sauer BG, Long MD. ACG clinical guideline: ulcerative colitis in adults. *Am J Gastroenterol* 2019;114:384-413.
  36. Peng X, Luo X, Hou JY, et al. Immunosuppressive agents for the treatment of primary sclerosing cholangitis: a systematic review and meta-analysis. *Dig Dis* 2017;35:478-485.
  37. Hommes DW, Erkelens W, Ponsioen C, et al. A double-blind, placebo-controlled, randomized study of infliximab in primary sclerosing cholangitis. *J Clin Gastroenterol* 2008;42:522-526.
  38. Reinisch W, Sandborn WJ, Hommes DW, et al. Adalimumab for induction of clinical remission in moderately to severely active ulcerative colitis: results of a enicrivir controlled trial. *Gut* 2011;60:780-787.
  39. Rutgeerts P, Sandborn WJ, Feagan BG, et al. Infliximab for induction and maintenance therapy for ulcerative colitis. *N Engl J Med* 2005;353:2462-2476.
  40. Hedin CR, Sado G, Ndegwa N, et al. Effects of tumor necrosis factor antagonists in patients with primary sclerosing cholangitis. *Clin Gastroenterol Hepatol* 2020;18:2295-2304.
  41. Tse CS, Loftus EV Jr, Raffals LE, Gossard AA, Lightner AL. Effects of vedolizumab, adalimumab and infliximab on biliary inflammation in individuals with primary sclerosing cholangitis and inflammatory bowel disease. *Aliment Pharmacol Ther* 2018;48:190-195.
  42. Biron A, Beaugerie L, Chazouillères O, Kirchgessner J. Impact of thiopurines and tumour necrosis factor antagonists on primary sclerosing cholangitis outcomes in patients with inflammatory bowel disease. *Aliment Pharmacol Ther* 2022;56:857-868.
  43. Jovani M, Danese S. Vedolizumab for the treatment of IBD: a selective therapeutic approach targeting pathogenic a4b7 cells. *Curr Drug Targets* 2013;14:1433-1443.
  44. Na SY, Kim YS. Management of inflammatory bowel disease beyond tumor necrosis factor inhibitors: novel biologics and small-molecule drugs. *Korean J Intern Med* 2022;37:906-919.
  45. Na SY, Choi CH, Song EM, et al. Korean clinical practice guidelines on biologics and small molecules for moderate-to-severe ulcerative colitis. *Intest Res* 2023;21:61-87.
  46. Lynch KD, Chapman RW, Keshav S, et al. Effects of vedolizumab in patients with primary sclerosing cholangitis and inflammatory bowel diseases. *Clin Gastroenterol Hepatol* 2020;18:179-187.
  47. Caron B, Peyrin-Biroulet L, Pariente B, et al. Vedolizumab therapy is ineffective for primary sclerosing cholangitis in patients with inflammatory bowel disease: a GETAID Multi-centre Cohort Study. *J Crohns Colitis* 2019;13:1239-1247.

48. Floreani A, De Martin S. Treatment of primary sclerosing cholangitis. *Dig Liver Dis* 2021;53:1531-1538.
49. Beuers U, Trauner M, Jansen P, Poupon R. New paradigms in the treatment of hepatic cholestasis: from UDCA to FXR, PXR and beyond. *J Hepatol* 2015;62(1 Suppl):S25-S37.
50. Beuers U. Drug insight: mechanisms and sites of action of ursodeoxycholic acid in cholestasis. *Nat Clin Pract Gastroenterol Hepatol* 2006;3:318-328.
51. Karlsen TH, Vesterhus M, Boberg KM. Review article: controversies in the management of primary biliary cirrhosis and primary sclerosing cholangitis. *Aliment Pharmacol Ther* 2014;39:282-301.
52. Lindor KD. Ursodiol for primary sclerosing cholangitis. Mayo Primary Sclerosing Cholangitis-Ursodeoxycholic Acid Study Group. *N Engl J Med* 1997;336:691-695.
53. Olsson R, Boberg KM, de Muckadell OS, et al. High-dose ursodeoxycholic acid in primary sclerosing cholangitis: a 5-year multicenter, randomized, controlled study. *Gastroenterology* 2005;129:1464-1472.
54. Lindor KD, Kowdley KV, Luketic VA, et al. High-dose ursodeoxycholic acid for the treatment of primary sclerosing cholangitis. *Hepatology* 2009;50:808-814.
55. Chapman MH, Thorburn D, Hirschfield GM, et al. British Society of Gastroenterology and UK-PSC guidelines for the diagnosis and management of primary sclerosing cholangitis. *Gut* 2019;68:1356-1378.
56. Wunsch E, Trottier J, Milkiewicz M, et al. Prospective evaluation of ursodeoxycholic acid withdrawal in patients with primary sclerosing cholangitis. *Hepatology* 2014;60:931-940.
57. Stiehl A, Rudolph G, Klötters-Plachky P, Sauer P, Walker S. Development of dominant bile duct stenoses in patients with primary sclerosing cholangitis treated with ursodeoxycholic acid: outcome after endoscopic treatment. *J Hepatol* 2002;36:151-156.
58. Ferreira MT, Ribeiro IB, de Moura DT, et al. Stent versus balloon dilation for the treatment of dominant strictures in primary sclerosing cholangitis: a systematic review and meta-analysis. *Clin Endosc* 2021;54:833-842.
59. Prokopić M, Beuers U. Management of primary sclerosing cholangitis and its complications: an algorithmic approach. *Hepatol Int* 2021;15:6-20.
60. Martin EF, Levy C. Timing, management, and outcomes of liver transplantation in primary sclerosing cholangitis. *Semin Liver Dis* 2017;37:305-313.
61. Gow PJ, Chapman RW. Liver transplantation for primary sclerosing cholangitis. *Liver* 2000;20:97-103.
62. Joshi D, Bjarnason I, Belgaumkar A, et al. The impact of inflammatory bowel disease post-liver transplantation for primary sclerosing cholangitis. *Liver Int* 2013;33:53-61.
63. Williamson KD, Chapman RW. New therapeutic strategies for primary sclerosing cholangitis. *Semin Liver Dis* 2016;36:5-14.
64. Fickert P, Hirschfield GM, Denk G, et al. norUrsodeoxycholic acid improves cholestasis in primary sclerosing cholangitis. *J Hepatol* 2017;67:549-558.
65. Halilbasic E, Fiorotto R, Fickert P, et al. Side chain structure determines unique physiologic and therapeutic properties of norursodeoxycholic acid in Mdr2<sup>-/-</sup> mice. *Hepatology* 2009;49:1972-1981.
66. Moustafa T, Fickert P, Magnes C, et al. Alterations in lipid metabolism mediate inflammation, fibrosis, and proliferation in a mouse model of chronic cholestatic liver injury. *Gastroenterology* 2012;142:140-151.
67. Modica S, Petruzzelli M, Bellafante E, et al. Selective activation of nuclear bile acid receptor FXR in the intestine protects mice against cholestasis. *Gastroenterology* 2012;142:355-365.
68. Kowdley KV, Vuppalanchi R, Levy C, et al. A randomized, placebo-controlled, phase II study of enicriviro acid for primary sclerosing cholangitis. *J Hepatol* 2020;73:94-101.
69. Trauner M, Gulamhusein A, Hameed B, et al. The nonsteroidal farnesoid X receptor agonist enicriviro (GS-9674) improves markers of cholestasis and liver injury in patients with primary sclerosing cholangitis. *Hepatology* 2019;70:788-801.
70. Assis DN, Abdelghany O, Cai SY, et al. Combination therapy of all-trans retinoic acid with ursodeoxycholic acid in patients with primary sclerosing cholangitis: a human pilot study. *J Clin Gastroenterol* 2017;51:e11-e16.
71. Lemoine S, Pares A, Reig A, et al. Primary sclerosing cholangitis response to the combination of fibrates with ursodeoxycholic acid: French-Spanish experience. *Clin Res Hepatol Gastroenterol* 2018;42:521-528.
72. ClinicalTrials.gov [Internet]. U.S. National Library of Medicine, 2022 [cited 2023 Jul 25]. <https://classic.clinicaltrials.gov/ct2/show/NCT04309773>
73. Eksteen B, Bowlus CL, Montano-Loza AJ, et al. Efficacy and safety of cenicriviroc in patients with primary sclerosing cholangitis: PERSEUS study. *Hepatol Commun* 2020;5:478-490.
74. ClinicalTrials.gov [Internet]. U.S. National Library of Medicine, 2017 [cited 2023 Jul 25]. <https://classic.clinicaltrials.gov/ct2/show/NCT03035058>
75. ClinicalTrials.gov [Internet]. U.S. National Library of Medicine, 2019 [cited 2023 Jul 25]. <https://clinicaltrials.gov/study/>

- NCT02239211
76. Stokkeland K, Höijer J, Bottai M, Söderberg-Löfdal K, Bergquist A. Statin use is associated with improved outcomes of patients with primary sclerosing cholangitis. *Clin Gastroenterol Hepatol* 2019;17:1860-1866.
  77. Bergquist A, Marschall HU, Nilsson E, et al. Long term effect of simvastatin in primary sclerosing cholangitis: a placebo-controlled, double-blind, multicenter phase III study (Piscatin). *Br J Gastroenterol* 2022;4:235-241.
  78. Muir AJ, Levy C, Janssen HL, et al. Simtuzumab for primary sclerosing cholangitis: phase 2 study results with insights on the natural history of the disease. *Hepatology* 2019;69:684-698.
  79. Färkkilä M, Karvonen AL, Nurmi H, et al. Metronidazole and ursodeoxycholic acid for primary sclerosing cholangitis: a randomized placebo-controlled trial. *Hepatology* 2004;40:1379-1386.
  80. Tabibian JH, Weeding E, Jorgensen RA, et al. Randomised clinical trial: vancomycin or metronidazole in patients with primary sclerosing cholangitis: a pilot study. *Aliment Pharmacol Ther* 2013;37:604-612.
  81. ClinicalTrials.gov [Internet]. U.S. National Library of Medicine, 2022 [cited 2023 Jul 25]. <https://clinicaltrials.gov/study/nct03710122>
  82. Vleggaar FP, Monkelbaan JF, van Erpecum KJ. Probiotics in primary sclerosing cholangitis: a randomized placebo-controlled crossover pilot study. *Eur J Gastroenterol Hepatol* 2008;20:688-692.
  83. Allegretti JR, Kassam Z, Carrellas M, et al. Fecal microbiota transplantation in patients with primary sclerosing cholangitis: a pilot clinical trial. *Am J Gastroenterol* 2019;114:1071-1079.
  84. Grygiel-Górniak B. Peroxisome proliferator-activated receptors and their ligands: nutritional and clinical implications: a review. *Nutr J* 2014;13:17.
  85. Ghonem NS, Ananthanarayanan M, Soroka CJ, Boyer JL. Peroxisome proliferator-activated receptor  $\alpha$  activates human multidrug resistance transporter 3/ATP-binding cassette protein subfamily B4 transcription and increases rat biliary phosphatidylcholine secretion. *Hepatology* 2014;59:1030-1042.
  86. Ghonem NS, Assis DN, Boyer JL. Fibrates and cholestasis. *Hepatology* 2015;62:635-643.
  87. Miyahara T, Schrum L, Rippe R, et al. Peroxisome proliferator-activated receptors and hepatic stellate cell activation. *J Biol Chem* 2000;275:35715-35722.
  88. Corpechot C, Chazouillères O, Rousseau A, et al. A placebo-controlled trial of bezafibrate in primary biliary cholangitis. *N Engl J Med* 2018;378:2171-2181.
  89. Ponsioen CY, Kuiper H, Ten Kate FJ, van Milligen de Wit M, van Deventer SJ, Tytgat GN. Immunohistochemical analysis of inflammation in primary sclerosing cholangitis. *Eur J Gastroenterol Hepatol* 1999;11:769-774.
  90. Hsu W, Zhang W, Tsuneyama K, et al. Differential mechanisms in the pathogenesis of autoimmune cholangitis versus inflammatory bowel disease in interleukin-2Ralpha(-/-) mice. *Hepatology* 2009;49:133-140.
  91. Mueller T, Beutler C, Picó AH, et al. Enhanced innate immune responsiveness and intolerance to intestinal endotoxins in human biliary epithelial cells contributes to chronic cholangitis. *Liver Int* 2011;31:1574-1588.
  92. Harada K, Nakanuma Y. Innate immunity in the pathogenesis of cholangiopathy: a recent update. *Inflamm Allergy Drug Targets* 2012;11:478-483.
  93. Zimmermann HW, Tacke F. Modification of chemokine pathways and immune cell infiltration as a novel therapeutic approach in liver inflammation and fibrosis. *Inflamm Allergy Drug Targets* 2011;10:509-536.
  94. Ye X, Liu S, Hu M, Song Y, Huang H, Zhong Y. CCR5 expression in inflammatory bowel disease and its correlation with inflammatory cells and  $\beta$ -arrestin2 expression. *Scand J Gastroenterol* 2017;52:551-557.
  95. Grant AJ, Lalor PF, Salmi M, Jalkanen S, Adams DH. Homing of mucosal lymphocytes to the liver in the pathogenesis of hepatic complications of inflammatory bowel disease. *Lancet* 2002;359:150-157.
  96. Rockey DC. Current and future anti-fibrotic therapies for chronic liver disease. *Clin Liver Dis* 2008;12:939-962.
  97. Schierwagen R, Uschner FE, Magdaleno F, Klein S, Trebicka J. Rationale for the use of statins in liver disease. *Am J Physiol Gastrointest Liver Physiol* 2017;312:G407-G412.
  98. Ikenaga N, Peng ZW, Vaid KA, et al. Selective targeting of lysyl oxidase-like 2 (LOXL2) suppresses hepatic fibrosis progression and accelerates its reversal. *Gut* 2017;66:1697-1708.
  99. Pollheimer MJ, Racedo S, Mikels-Vigdal A, et al. Lysyl oxidase-like protein 2 (LOXL2) modulates barrier function in cholangiocytes in cholestasis. *J Hepatol* 2018;69:368-377.
  100. Nakamoto N, Sasaki N, Aoki R, et al. Gut pathobionts underlie intestinal barrier dysfunction and liver T helper 17 cell immune response in primary sclerosing cholangitis. *Nat Microbiol* 2019;4:492-503.
  101. Hole MJ, Jørgensen KK, Holm K, et al. A shared mucosal gut

- microbiota signature in primary sclerosing cholangitis before and after liver transplantation. *Hepatology* 2023;77:715-728.
102. Kummen M, Holm K, Anmarkrud JA, et al. The gut microbial profile in patients with primary sclerosing cholangitis is distinct from patients with ulcerative colitis without biliary disease and healthy controls. *Gut* 2017;66:611-619.
103. Sabino J, Vieira-Silva S, Machiels K, et al. Primary sclerosing cholangitis is characterised by intestinal dysbiosis independent from IBD. *Gut* 2016;65:1681-1689.
104. Shah A, Crawford D, Burger D, et al. Effects of antibiotic therapy in primary sclerosing cholangitis with and without inflammatory bowel disease: a systematic review and meta-analysis. *Semin Liver Dis* 2019;39:432-441.
105. Quaranta G, Guarnaccia A, Fanello G, et al. Fecal microbiota transplantation and other gut microbiota manipulation strategies. *Microorganisms* 2022;10:2424.